



PATIENT

Zombie Banks

SPECIES

Canine

BREED

Chihuahua

SEX

MN

AGE

13 y

WEIGHT

3.3 kg

PRESENTING CLINICAL SIGNS

Grade 3/5 murmur. Previously diagnosed with stage B1 degenerative valve disease.

ECHOCARDIOGRAPHIC FINDINGS

2D, M-mode, and Doppler study.

There is mild left atrial dilation. The mitral valve leaflets are thickened and exhibit systolic prolapse. A mild to moderate jet of eccentric mitral regurgitation is present. There is mild left ventricular dilation. Left ventricular systolic function is hyperdynamic. The aorta and aortic valve are normal. Right atrial and right ventricular dimensions are normal. The tricuspid valve leaflets are mildly thickened, and a mild jet of tricuspid regurgitation is present. The pulmonary artery and pulmonic valve are normal. No shunting lesions are visualized. No pericardial effusion or cardiac masses are seen.

LA - 26.4 mm
LVIDd - 26.0 mm
LVIDs - 12.5 mm
FS - 51.9%
RA - 12.3 mm
LVOT - 0.86 m/s
RVOT - 0.70 m/s

INTERPRETED BY

Keith Blass, DVM, MS,
DACVIM (Cardiology)

IMAGING PERFORMED BY

Amanda Stewart

HOSPITAL NAME

Acton AC

REFERRING VET

Dr. Poremba

INVOICE

DATE

1/9/26

ASSESSMENT/RECOMMENDATIONS

Degenerative mitral (stage B2) and tricuspid (stage B1) valve disease

This examination demonstrates mild progression of Zombie's mitral valve disease over the past year and a half, and he now has mild secondary dilation of both his left atrium and left ventricle. As only mild dilation is present, Zombie's current risk for the development of clinical signs secondary to his mitral valve disease, such as coughing, exercise intolerance, syncope, and labored breathing, still appears to be relatively low, though careful monitoring for these signs is recommended.

Zombie's tricuspid valve disease is still mild and well-compensated.

I recommend starting Zombie on pimobendan (1.25 mg am, 0.625 mg pm), as this medication should help to slow the progression of his mitral valve disease.

A recheck echocardiogram is recommended in 9 months. Thoracic radiographs are recommended if Zombie experiences respiratory clinical signs.



PATIENT

Zombie Banks

SPECIES

Canine

BREED

Chihuahua

SEX

MN

AGE

13 y

WEIGHT

3.3 kg

INTERPRETED BY

Keith Blass, DVM, MS,
DACVIM (Cardiology)

IMAGING PERFORMED BY

Amanda Stewart

HOSPITAL NAME

Acton AC

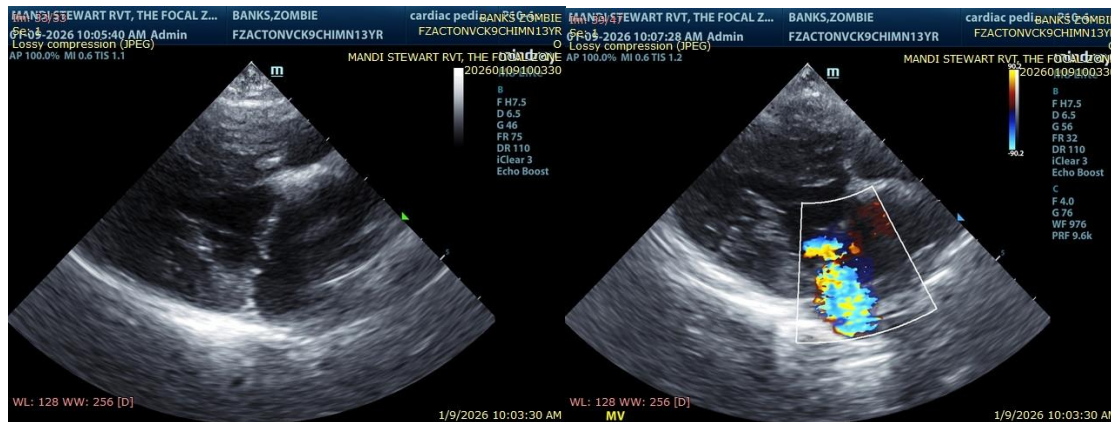
REFERRING VET

Dr. Poremba

INVOICE

DATE

1/9/26



The information and recommendations provided are based on the images presented by the referring veterinarian/sonographer. No evaluation can be communicated regarding pathology that was not visible in the image/video clips provided.

Thank you for this referral. If the clinical or image interpretation does not parallel your findings or if I can be of any further assistance please contact me.

Keith Blass, DVM, MS, DACVIM (Cardiology)

info@SonoPath.com